

CASE REPORT

Retrograde transcatheter closure of anterior mitral valve leaflet perforation

Berke Sengun¹, Işıl Yıldırım¹, Ömer Yıldız², Alpay Çeliker¹

¹Department of Pediatric Cardiology, Koç University School of Medicine, Istanbul, Turkey, ²Department of Cardiology, Koç University School of Medicine, Istanbul, Turkey

ABSTRACT

Transcatheter closure of mitral valve leaflet perforation is a very rarely performed and a difficult procedure for repairing the defect. Herein, we are the first to report on both the safety and feasibility of percutaneous retrograde transcatheter closure of anterior mitral valve leaflet perforation with an AMPLATZER™ Duct Occluder II (6 mm × 6 mm, ADO II; Abbott Vascular, IL, USA) device in a 19-year-old patient with a severe mitral valve regurgitation following cardiac surgery.

Keywords: Duct occluder, mitral regurgitation, mitral valve perforation, transcatheter closure, valvular defect

INTRODUCTION

Mitral valve perforations have been reported in patients following cardiac surgery, infective endocarditis, autoimmune diseases, and in patients who underwent transcatheter aortic valve replacement (TAVR).^[1-3] Spontaneous mitral valve defects are very rarely observed.^[4] Perforations are usually treated with the surgical approach. In this report, we describe the feasibility of percutaneous retrograde transcatheter closure of an anterior mitral valve perforation with an AMPLATZER™ Duct Occluder II (6 mm × 6 mm, ADO II; Abbott Vascular, IL, USA) device.

CASE REPORT

A 19-year-old patient, diagnosed with Ehler-Danlos syndrome, underwent patent ductus arteriosus closure and secundum atrial septal defect (ASD) repair when she was 6 months and 3 years old, respectively. Primary repair with continuous stitches closed the 3 cm × 3 cm secundum ASD. No abnormality was

observed in the mitral valve during the operation. Over regular postoperative follow-up, a new onset of mitral regurgitation through the anterior mitral valve leaflet was discovered. The patient did not have any history of infective endocarditis or any other underlying medical pathology that might explain the perforation. Therefore, it was considered an iatrogenic injury from the previous ASD correction. Being followed up for newly discovered mitral valve regurgitation, her symptoms of dyspnea and fatigue on exertion became worse over time. The transthoracic echocardiography revealed normal-sized left ventricle (LV) (43.3 mm, Z-score -0.26) and enlarged left atrium (LA) (38 mm, Z-score 3.11) with moderate-to-severe mitral regurgitation (regurgitant Jet Area 34%). Transesophageal echocardiography (TEE) was performed to evaluate the accurate anatomy of mitral regurgitation which demonstrated a small perforation (3 mm × 6 mm) at the base of the anterior mitral leaflet [Figure 1]. Utilizing three-dimensional echocardiography, the perforation was shown to be circular and thus deemed eligible for transcatheter device closure. In view of the invasiveness of mitral

Video available on: www.annalspc.com

Access this article online

Quick Response Code:



Website:

www.annalspc.com

DOI:

10.4103/apc.APC_162_18

This is an open access journal, and articles are distributed under the terms of the Creative Commons Attribution-NonCommercial-ShareAlike 4.0 License, which allows others to remix, tweak, and build upon the work non-commercially, as long as appropriate credit is given and the new creations are licensed under the identical terms.

For reprints contact: reprints@medknow.com

How to cite this article: Sengun B, Yıldırım I, Yıldız Ö, Çeliker A. Retrograde transcatheter closure of anterior mitral valve leaflet perforation. *Ann Pediatr Card* 2019;12:312-4.

Address for correspondence: Dr. Alpay Çeliker, Amerikan Hastanesi Güzelbahçe Sok, No: 20 34365 Nisantasi, Istanbul, Turkey.

E-mail: alpayceliker@gmail.com

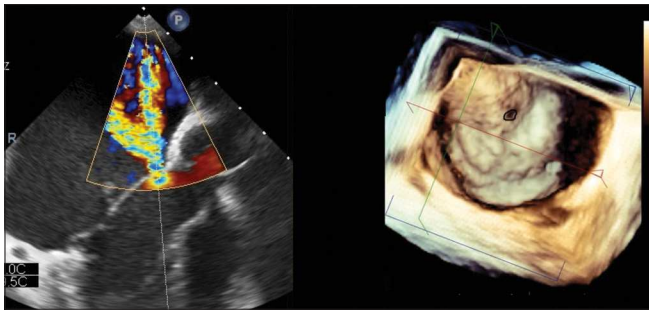


Figure 1: Transesophageal echocardiography: The procedure revealed a moderate size regurgitation (left) and a circular defect on three-dimensional reconstruction (right)

valve repair by cardiothoracic surgery and the suitable size anatomy of the perforation, we decided to perform transcatheter device closure.

Under general anesthesia, with the guidance of TEE and fluoroscopy, the procedure started with the right femoral artery (6F) and vein (6F) cannulation. Heparin infusion and activated clotting time monitoring were done. Using the femoral artery approach, the LV was accessed through the aorta. During the hemodynamic examination, the chamber pressures were detected as, right atrium: mean 7 mmHg LA: mean 17 mmHg, right ventricle: 38/0–5 mmHg, and LV 80/0–5 mmHg; pulmonary artery: 32/21 mmHg – mean 26 mmHg, and aorta: 71/55 mmHg – mean 63 mmHg.

After performing the left ventriculography, utilizing a 6 F pigtail catheter, a regurgitant jet through the mitral valve was detected. Through the right femoral vein approach, we performed transseptal puncture (BRK™-Abbott Vascular, IL, USA) to obtain access to the LA. Then, small volume of contrast agent was injected into the LA, to verify the position of the catheter. There was only regurgitation and no forward flow from LA to LV; hence, the attempts to pass through the defect with the anterograde approach were highly unlikely. We tried to perform the anterograde approach anyway because it was safer. However, despite trying out different catheters and floppy guidewires, the defect could not be advanced anterogradely. Subsequently, using a 5 F right Judkins catheter and 0, 14" floppy guidewire, the defect was easily crossed in retrograde fashion. We tried to catch the guidewire with Amplatzer Gooseneck Snare (Abbott Vascular, IL, USA) that was guided from the LA to create an AV loop. After several attempts and brief recurrent periods of atrial tachycardia attacks, we planned to proceed with the retrograde implantation. By utilizing coronary guidewire, a 5F delivery catheter was advanced from the aorta into the LV and then into the LA, respectively. Amplatzer Duct Occluder II (6 mm × 6 mm, Abbott Vascular, IL, USA) device was advanced through the delivery catheter. First, the LA disc of the device was opened followed by the LV disc. The procedure steps were controlled with TEE monitoring

for aortic regurgitation and appropriate device landing. Since the discs were in place, a small regurgitant jet was observed through the device, but the size and placement of the device were considered successful, and the procedure was finished by unscrewing the delivery system from the device. In the follow-up period, mitral and aortic valves were observed as normal, and no complications developed associated with the procedure. The patient has been followed up with acetylsalicylic acid 250 mg/day. At the last follow-up, 8 months after the procedure, residual regurgitation (regurgitant Jet area 4%) was observed in the corrected mitral valve defect, and LA diameter decreased to 31 mm (Z-score 1.6) [Video 1].

DISCUSSION

Perforations in the mitral valve leaflets are very rare with a scarcity of data published in the literature. Many etiologies can cause structural defects in mitral valves such as repair of atrioventricular septal defects, TAVR, repair of infective endocarditis sequelae and previous history of cardiac surgery. However, perforations of the anterior mitral valve leaflet are very rarely caused by iatrogenic injuries. In a prior study, of 475 patients with aortic valve insufficiency surgical repair procedure, only two patients had anterior mitral valve leaflet perforations as a postoperative complication.^[4]

Mitral valve leaflet defects are usually managed by the surgical approach with potentially severe complications for patients. Although transcatheter closure of mitral paravalvular leaks has become an established treatment option, there are only three reported cases in the literature that describes in contrast to our report an antegrade transcatheter approach for mitral leaflet perforations. In the first report, an 8 mm AMPLATZER ASD septal occluder device (Abbott Vascular, IL, USA) was used for sealing the defect in anterograde fashion, after two MitraClips (Abbott Vascular, IL, USA) were implanted in an adult patient with severe mitral regurgitation.^[5] Another report describes a 15-year-old patient, who underwent the postneonatal repair of truncus arteriosus and sustained an anterior leaflet mitral valve injury during elective aortic root replacement and aortic valve repair, resulting in severe mitral regurgitation. A 22-mm Amplatzer vascular plug type II (Abbott Vascular, IL, USA) was successfully deployed anterogradely across both the atrial septum and the mitral valve defects. The patient died due to cerebral hemorrhage not related to cardiac status.^[6] The last report describes closure of perforation at the base of the posterior leaflet by the anterograde approach, using 6 mm × 4 mm ADO II (Abbott Vascular, IL, USA) in an adult patient with end-stage kidney failure.^[7]

Clinical scenarios that present in unusual circumstances can provoke clinicians to try new methods to solve particular challenges. Up to date, this is the first

Sengun, *et al.*: Transaortic repair of mitral valve perforation

description of a retrograde approach for the closure of anterior mitral valve leaflet perforation with the Amplatzer Duct Occluder II device. Eight months after the procedure, our patient is currently healthy with only a residual mitral regurgitation. However, the closure of cardiac defects by a nitinol occluder device is associated with endothelialization of the device which might theoretically lead to fibrosis of the leaflets with impairment of the mobility of the leaflets; therefore, the long-term assessment is needed in these young patients.

CONCLUSION

Percutaneous retrograde transcatheter closure of anterior mitral valve leaflet perforations is feasible. In terms of safety, it needs long-term follow-up. Meanwhile, it can motivate other physicians to perform a more reliable procedure for the repair of mitral valve perforations in suitable patients as well as supplying additional information for physicians who treat structural cardiac valve defects.

Declaration of patient consent

The authors certify that they have obtained all appropriate patient consent forms. In the form the patient(s) has/have given his/her/their consent for his/her/their images and other clinical information to be reported in the journal. The patients understand that their names and initials will not be published and due efforts will be made to conceal their identity, but anonymity cannot be guaranteed.

Financial support and sponsorship

Nil.

Conflicts of interest

There are no conflicts of interest.

REFERENCES

1. Stout KK, Verrier ED. Valvular heart disease: Changing concepts in disease management; acute valvular regurgitation. *Circulation* 2009;119:3232-41.
2. Bouma W, Klinkenberg TJ, van der Horst IC, Wijdh-den Hamer IJ, Erasmus ME, Bijl M, *et al.* Mitral valve surgery for mitral regurgitation caused by libman-sacks endocarditis: A report of four cases and a systematic review of the literature. *J Cardiothorac Surg* 2010;5:13.
3. Cozzarin A, Cianciulli TF, Guidoin R, Zhang Z, Lax JA, Saccheri MC, *et al.* CoreValve prosthesis causes anterior mitral leaflet perforation resulting in severe mitral regurgitation. *Can J Cardiol* 2014;30:1108.e11-3.
4. Van Dyck M, Glineur D, de Kerchove L, El Khoury G. Complications after aortic valve repair and valve-sparing procedures. *Ann Cardiothorac Surg* 2013;2:130-9.
5. Czerny M, Taramasso M, Guidotti A, Maisano F. A creative transcatheter approach to correct complex recurring mitral regurgitation after previous surgical repair. *Euro Interv* 2016;11:1302-4.
6. Grant EK, Kim DW, Border WL, Lerakis S, Babaliaros V, Vincent RN. Transseptal anchored vascular plug closure of mitral valve perforation. *JACC Cardiovasc Interv* 2017;10:45-6.
7. Goswami R, Colin B, Jackson M, Kleiman N, Little S. Transesophageal echocardiography-guided percutaneous intervention for a mitral valve leaflet perforation. *JACC Cardiovasc Interv* 2015;8:754-5.